

MIBG Negative Pheochromocytoma

Nihar Mehta*, V Paniker**, Arpit Shah***

Abstract

We present a case of a left sided pheochromocytoma, who had normal levels of 24 urinary vanillylmandelic acid and a normal MIBG scan. The diagnosis was confirmed on histopathology of the adrenal gland.

Introduction

Pheochromocytomas are catecholamine secreting tumours arising from chromaffin cells. Majority of them arise in the adrenal medulla. They present with hypertension or arrhythmias. Their diagnosis is established by measuring plasma metanephrine or catecholamine levels or by measuring 24 hour urinary metanephrine or vanillylmandelic acid levels. Localization of the tumour is done using CT scans or MRI scans. One of the most specific tests is a meta-iodobenzylguanidine scan (MIBG scan).¹

Case Report

A 40 year old female presented with headache since 3 years, the headache being generalized, non-radiating, no aggravating or relieving factors and no aura preceding the headache. No history of episodic worsening or sweating or flushing attacks. The patient complained of palpitations, regular in nature, intermittently, with no apparent aggravating or relieving factors. No chest pain. No history of any neurological symptoms.

On examination, she was conscious cooperative. Her pulse was 94 per minute, blood pressure was 240/140mm Hg, and respiratory rate was 16/minute. She was pale, had no edema and normal jugular venous pressure. There was no carotid bruit. Cardiovascular examination revealed tachycardia. There was no murmur. Other systemic examination showed no abnormality. No neck rigidity. Fundoscopy showed Grade 4 hypertensive retinopathy without papilloedema.

Laboratory investigation were as follows; Hemoglobin was 8.8 g/dl (MCV 54.4fl, MCH 18.9 pg, MCHC 34.6%), WBC count 7700/c.mm (neutrophil - 77%, lymphocytes - 22%, monocytes - 1%), platelet count 2.79,000/c.mm, blood glucose 90 mg/dl, serum calcium was 7.8 mg/dl, serum creatinine was 0.9mg/dl, serum phosphorus was 4.5 mg/dl, serum sodium 137 mEq/L, serum potassium 4.6 mEq/L, serum uric acid was 5 mg/dl, urine routine was normal. The electrocardiography showed left ventricular hypertrophy with strain. Chest X Ray was normal. 2D Echocardiography showed hypertensive heart disease with

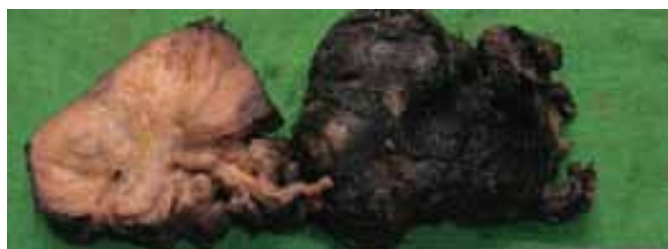

Fig. 1 : Specimen of Left Adrenal Gland showing Pheochromocytoma

*Senior Resident, **Professor, ***Intern, Department of Medicine, K.J. Somaiya Hospital and Research Centre, Eastern Express Highway, Sion, Mumbai 400 022

Received: 12.09.2009; Revised: 18.12.2009; Accepted: 21.12.2009

concentric left ventricular hypertrophy with a left ventricular ejection fraction of 65%. No valvular abnormality or regional wall motion abnormality.

The ultrasonography of the abdomen revealed normal kidney sizes bilaterally. There was a 4.6cm by 3.2cm well defined hypo echoic lesion anterior to the left kidney with minimal vascularity. Renal Artery Doppler was normal. The C.T. Scan of the abdomen (plain with contrast) revealed a well defined 4.5cm by 3.8cm by 3.1cm nodular mass involving the left adrenal gland with gradual enhancement with early wash out, morphology suggestive of Pheochromocytoma. The MIBG scan report quoted 'No MIBG concentration in the left adrenal mass and a MIBG concentration in the right adrenal area that might be normal'. 24 Hour Urinary Vanil Mandelic Acid levels were 2.6 mg/day (normal - less than 15mg/day).

The patient was put on multiple drugs to control her hypertension - Prazopressin 5mg B.D., Nifedipine - Retard 10mg Q.D.S., Metoprolol 25 mg B.D. and Hydrochlorothiazide 12.5mg B.D. Her blood pressure was reduced to 140/90mmHg.

The patient was taken up for left adrenalectomy.

The histopathology of the left adrenal gland revealed a Benign Pheochromocytoma. See Figures 1,2 and 3.

Post operatively, the patient developed a blood pressure of 140/94mmHg, which was treated with Enalapril 5mg B.D. She follows up regularly every month, asymptomatic, with a blood pressure of 130/80 mmHg.

Discussion

Pheochromocytoma is a rare catecholamine secreting tumour arising from the adrenal medulla in 80-85% of cases. Pheochromocytomas present with sustained or paroxysms of hypertension, due to catecholamine release.

The biochemical diagnosis of pheochromocytoma is made by measuring plasma free metanephrines or 24 hour urine fractionated metanephrines. Other tests include plasma catecholamines and 24 hour urinary catecholamines, total metanephrines and vanillylmandelic acid which have a lower specificity. Among these, the specificity is highest for 24 hour urinary vanillylmandelic acid and for 24 hour urinary total metanephrines (93%)². The sensitivity and specificity of these are given in Table 1.

Plasma metanephrines should be the biochemical test of choice in diagnosis of pheochromocytoma since they have a sensitivity of 99%

Ultrasonography of the abdomen, C.T. scans with contrast enhanced images and M.R.I. scans are used to localize adrenal pheochromocytomas.^{3,4} [¹²³I/¹³¹I] M.I.B.G. scintigraphy should be performed after the tumour has been localized by C.T. scan or M.R.I. scan to rule out any extra adrenal paraganglioma. The sensitivity and specificity of these are given in Table 2.

Our patient had normal levels of 24 Hour Urinary Vanil

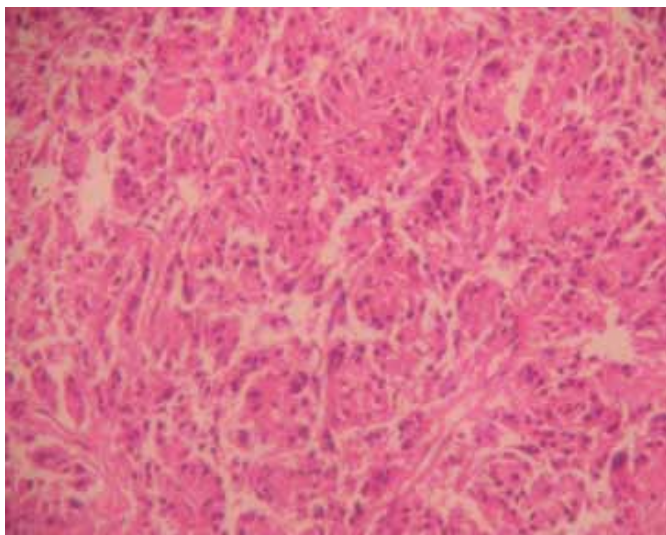


Fig. 2 : Histopathology Slide of the Pheochromocytoma

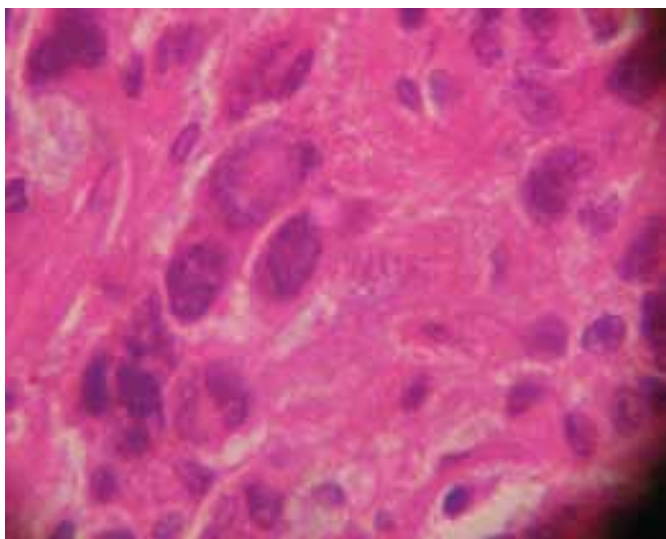


Fig. 3 : Histopathology Slide of the Pheochromocytoma

Mandelic Acid and a normal MIBG scan. These are the most specific tests for the diagnosis of pheochromocytoma.

MIBG imaging is considered the 'gold standard' in localization of pheochromocytomas but it can be negative in 15% of cases of benign pheochromocytoma and in 50% of cases of malignant pheochromocytoma⁵. Therefore in patients who are suspected to have a pheochromocytoma but have a negative MIBG scan should be subjected to PET scanning (6-[¹⁸F]fluorodopamine

Table 1 : Sensitivity and Specificity of Biochemical Studies^{7,15}

	24- Hour Urinary VMA	24- Hour Urinary Metanephrine	Plasma Free Metanephrines
Sensitivity	64%	77%	99%
Specificity	95%	93%	89%

Table 2 : Sensitivity and Specificity of Imaging studies^{1,9,10,14}

	Ultrasonography	CT-CSI	MRI	PET*#	MIBG
Sensitivity	83-89%	98%	93-100%	89%	77-90%
Specificity	60%	92%	50%	96%	95-100%

positron emission tomography) for confirmation and to detect any extra adrenal paraganglioma which might require removal along with the adrenal pheochromocytoma. They also detect malignancy or metastasis, which might render the patient inoperable.

Conclusion

In conclusion, plasma metanephrine levels are the biochemical test of choice in diagnosis of Pheochromocytomas and PET scans should be used in MIBG negative Pheochromocytomas to confirm the diagnosis and rule out extra adrenal paragangliomas or malignancy.

References

1. A meta-iodobenzylguanidine scintigraphic scoring system increases accuracy in the diagnostic management of pheochromocytoma by D Cecchin, F Lumachi, M C Marzola, G Opocher, C Scaroni, P Zucchetta, F Mantero and F Bui. *Endocrine-Related Cancer* DOI:13 (2) 525-533 10.1677/erc.1.01066
2. Lenders JW, Pacak K, Walther MM, Linehan WM, Mannelli M, Friberg P, Keiser HR, Goldstein DS & Eisenhofer G 2002 Biochemical diagnosis of pheochromocytoma:-which test is best? *JAMA* 287 1427-1434 March 20, 2002.
3. Current Approaches and Recommended Algorithm for the Diagnostic Localization of Pheochromocytoma Ioannis Ilias and Karel Pacak. *The Journal of Clinical Endocrinology & Metabolism* Vol. 89, No. 2 479-491
4. Diagnosis and management of tumors of the adrenal medulla. Ilias I, Pacak K. *Hormone Metabolism and Research*. 2005 Dec;37(12):717-21
5. The use of 18-fluoro-dihydroxyphenylalanine and 18-fluorodeoxyglucose positron emission tomography scanning in the assessment of metaiodobenzylguanidine-negative pheochromocytoma. I S Mackenzie, M Gurnell, K K Balan, H Simpson, K Chatterjee and M J Brown. *European Journal of Endocrinology*, Vol 157, Issue 4, 533-537.